

Omphalitis Leading to Urachitis and Acute Vascular Changes in a Buffalo Calf: An Insight into Macro and Microscopic Pathologic Changes

Sidhartha Deshmukh*, Harmanjit Singh Banga, Sneha Thorat and Rajinder Singh Brar

Department of Veterinary Pathology, College of Veterinary Science, Guru Angad Dev Veterinary and Animal Sciences University, Ludhiana-141004, Punjab, India

Abstract: Omphalitis in domestic animals being considered as commonest ailment after birth, are in general, poorly reported for its uneventful recovery. Several previously reported cases endeavoured to highlight involvement of pathogenic organism in progression of the condition with little elaboration to pathologic changes occurred. Moreover, description of omphalitis in buffalo calf was never been attempted. Therefore this report intends to elaborate the pathology noted around umbilical zone in a buffalo calf possibly arisen to infectious etiology with special reference to complicated involvement of urachus, eventual haemoperitoneum and striking acute vascular changes of multi-systemic organs. Intriguingly, this report also attempted to review few recent cases of omphalitis seen in different animals along with their paramount etiologic causes.

Keywords: Omphalitis, Urachitis, Pathology, Buffalo calf.

INTRODUCTION

Omphalitis in new born animal also known as "Naval ill", is the inflammation of umbilical structures [1]. This condition is more commonly seen in calves after birth. During birth at the organized farms, the umbilical cord is surgically detached from the maternal attachment and clamped temporally to hasten its natural closure and involution. Poor farm managemental practice(s) are responsible for high rise of omphalitis/omphalophlebitis in the animals due to contaminated floorings which contains lot of microbes. This later result in urachitis, peritonitis, septicaemia and death of the animal [2]. The condition is not uncommon, however pathologic description to inflammatory/circulatory changes in an around umbilicus, besides affections to other splanchnic, systemic organs is less and poorly elaborated. Majority of reports on "navel ill" or "omphalitis" are confined to young cattle calves, foals, goat kids or in sheep [1, 3, 4]. Similar to other animals, buffalo calves also gets infected and suffer from omphalitis. A glance at previous literatures and notes revealed sparse information about omphalitis in buffalo species. Through this report, an attempt was made to discuss various possible pathological changes noted in umbilical zone leading to urachitis as well as pathologic manifestations in other important organs of the body.

CASE HISTORY

A dead, week old (7 days) buffalo calf was brought for post mortem in Department of Veterinary Pathology, GADVASU, Ludhiana. The animal was supplied with inconclusive history of low feed intake, before death and also with no prior history of diarrhoea or constipation associated with this case.

On external examination, the most prominent pathologic change noted around umbilical zone was swollen umbilicus with encircled area of vascular congestion peripheral to its opening (i.e. ring like outline). The carcass in general appeared dehydrated with rough body coat. On opening, the carcass showed massive generalized vascular congestion and haemorrhagic changes in splanchnic organs confined to peritoneal and pelvic cavity (Figure 1). The urachus that connects prenatal allantois with dome of urinary bladder during foetal life exhibited edematous thickening with massive haemorrhages. Additionally, shreds of clotted blood noted were also scrapped out from the peritoneal as well as pelvic cavity i.e. haemoperitoneum.

The lungs showed widespread hyperaemic changes and focal areas of haemorrhages at cranio-ventral aspects on the both sides of the mediastinum. Right hand side heart appeared dilated with prominent ramification by coronary blood vessels and with other smaller collateral vessels. The stomach exhibited congestive changes on its luminal surface. Large intestine particularly colon exhibited marked mural thickening towards terminal end with evidence of fibrinous adhesions at its serosal surface besides red

*Address correspondence to this author at the Department of Veterinary Pathology, College of Veterinary Science, Guru Angad Dev Veterinary and Animal Sciences University, Ludhiana-141004, Punjab, India; Tel: (+91) 0161-2414027; Fax: (+91)(0161)-2414022; E-mail: sid0159@yahoo.com

haemorrhagic streaks. Liver exhibited autolytic changes. There was renomegaly on both sides with accumulation of clotted blood in and out of the organ including renal pelvis. Adrenals displayed slight enlargement with haemorrhages. The urinary bladder was markedly haemorrhagic and was massively engorged with urine mixed with bloody contents.

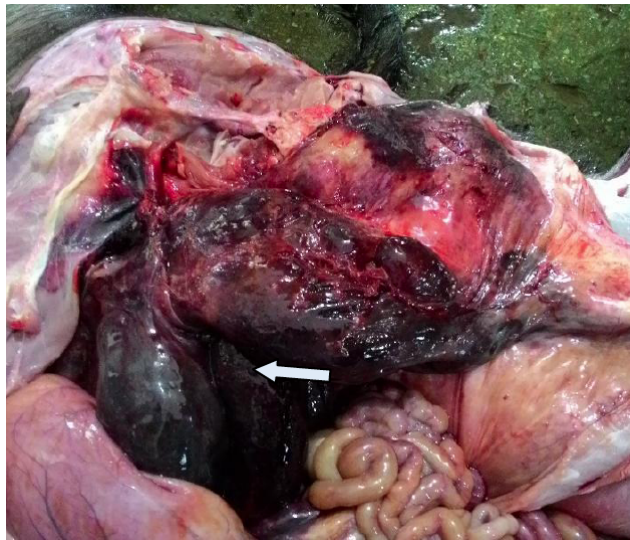


Figure 1: Haemoperitoneum (arrow) with highly haemorrhagic urinary bladder and clotted blood.

MATERIAL AND METHODS

A full necropsy was performed and representative tissue samples were immediately collected in 10% neutral buffered formalin and processed by standard histopathological techniques [5] and embedded in paraffin wax. Sections were finally made at 4-6 μ thick and were stained with haematoxylin and eosin (H&E). Gram staining was also attempted to visualize the presence of bacterial organisms.

RESULTS AND DISCUSSION

Practically in the field situation, medical attention given to the conditions like omphalitis (Naval ill) in animal is almost unenthusiastic, probably being the commonest ailment seen in neonates after birth and also for its uneventful recovery, if attended cautiously thereafter. Incidentally, the case as such on omphalitis in buffalo calves to our knowledge has never been academically abstracted. Thus this report, intends to discuss omphalitis in a buffalo calf, with special focus on urachus with associated inflammatory changes and other possible pathological complications noted.

The umbilical cord being an important connection between foetal circulation with maternal vascular

supply always remains a sensitive portal of entrance for various environmental pathogens following its natural or induced severance after birth. Therefore, during lackadaisical management, spread of infections occurs through patent umbilical opening that finally serves as a platform for localization, subsequent systemic dissemination of pathogenic organism inside the body. The present case exhibited almost similar condition when examined at gross and microscopic level. Incidentally, the umbilical artery with large quantity of collagen, elastic fibres, fibroblasts at its wall that constitutes the central area of umbilical cord was presented with marked clogging of its lumen by RBCs (Figure 2). There was severe, massive areas of frank haemorrhages across the umbilical mesenchyme that leads to its peripheral distension, with fresh fibrinous deposits. The collateral veins and *vasa vasorum* of umbilical artery showed presence of bacterial deposits in their wall (Figures 3 and 4). In urachus, massive

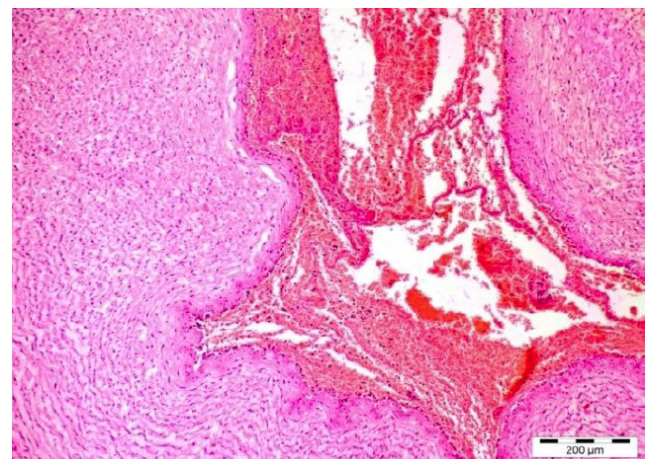


Figure 2: Umbilical artery, note the star shaped intima, containing massive numbers of red blood cells, H&E x20.

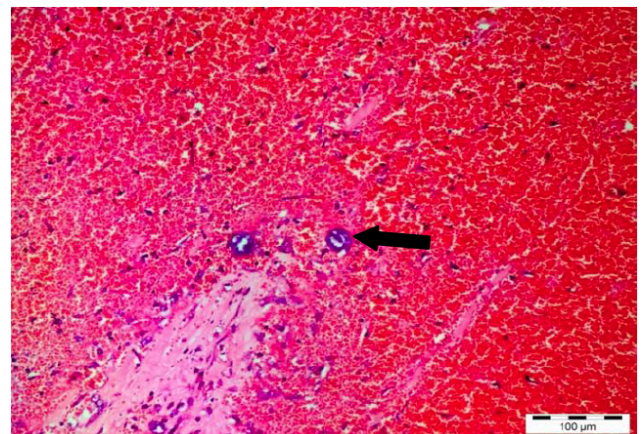


Figure 3: Umbilical artery, *Vasa vasorum* showing bacterial organism within, surrounded with massive haemorrhagic mesenchyme, H&E x20.

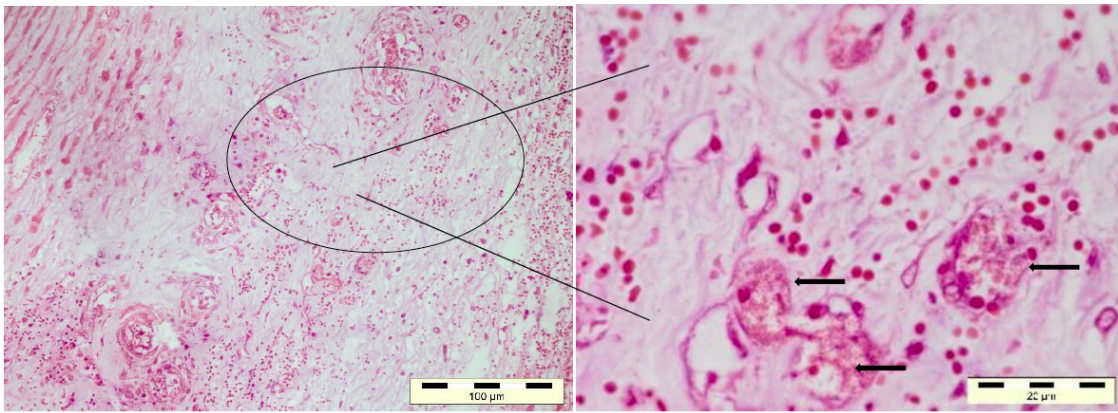


Figure 4: *Vasa vasorum* showing bacterial organism within vessels, Gram's Stain x 20. Inset: 4same section at higher magnification showing bacterial organisms (arrow).

stretches of fibrino-necrotic zone lying beneath the necrotic epithelial surface were noted (Figure 5). Several to many areas of severe perivascular lymphoplasmacytic infiltrate were found within fibrous connective tissue and abundant degenerative neutrophils were seen near the mucosal lining. Additionally, areas of vascular thrombus were also noted. Being in proximity to the inlet of umbilical cord at an oblique position in splanchnic side, both urinary bladder and kidney showed prominent haemorrhagic changes, which were further characterized by cortical pitting due to focal as well as generalized accumulation of capsular haemorrhages besides widespread degenerative changes in cortical as well as medullary zones. Adrenal glands too displayed similar changes at its capsular region. There was marked purulent cystitis (urinary bladder) with progressive combinatorial cellular changes that indicated its headway towards chronic suppurative condition. The mural thickening, necrosis within urinary bladder and suffuse haemorrhagic zones over kidney and urinary bladder, besides adrenals suggests that pelvic organs to bear the first pathologic

manifestations followed by umbilical disturbances. It is a known fact that ascending infections/insults emerging from infected umbilicus, results in serious septicemic and pyogenic condition like swelling of joints as arthritis, in brain as meningitis with convulsive seizures and in heart as endocarditis [6-8] respectively. In this report, bacterial isolation was not carried out, thus the incriminating bacterial organism(s) is / are not known. However, the lesions as well as nature of cellular infiltration noted are suggestive of a bacterial infection. In earlier communications, held across the globe, on similar pathology, in different domestic animals, suggested participation by anaerobic bacterium in concert with secondary invaders for such causal pathologic lesions as well as, acute systemic vascular alterations [9,10]. Additionally, we cannot, however, rule out the present attributable tissue changes observed consequent to the action of toxins produced by aerobic or anaerobic bacteria, apart from causation of serious systemic changes. The microscopic changes observed in lungs and heart consisted of pleural haemorrhages, alveolar thickening with widespread

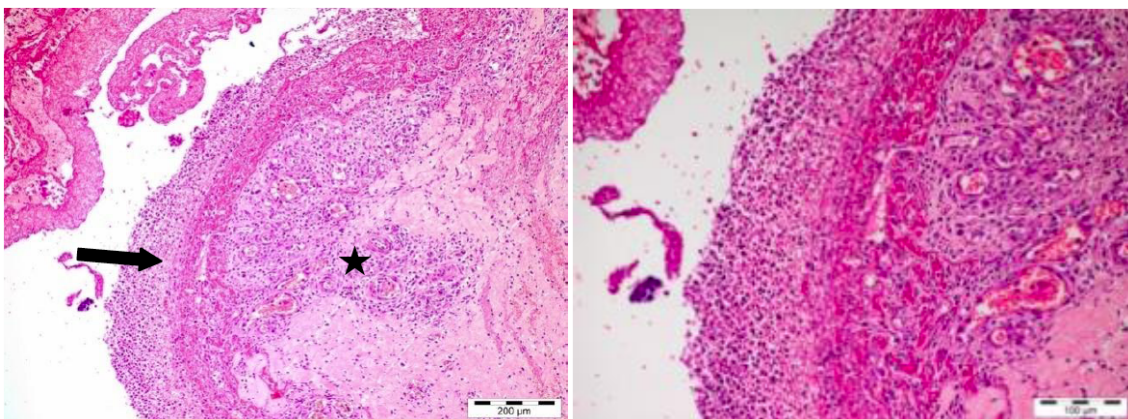


Figure 5: Urachus, Necrotic epithelium over the fibrino- necrotic zone (arrow). Note the perivascular lympho-plasmacytic infiltration within fibrous connective tissues (Black star), H&E x20. Inset a: Same section at higher magnification.

hyalinosis (Figure 6) and dilated coronary arteries respectively. The detected gross lesions are an innuendo to the pathogenic insult inflicted in this case is of acute toxic type owing to bacterial propagation that is inevitable. There were multiple areas of haemorrhages and loss of epithelium at the illeo-cecal junction with perivascular infiltration by polymorphonuclear cells. Incidentally, such observed tissue changes in intestinal tract are believed to occur due to its proximity to umbilical zone as well as its position underneath to the pelvic organs. The sudden death noted in this animal further supports hypothesis that the acute pathologic manifestation noted i.e. massive vascular congestion of major organs with concomitant haemoperitoneum could be an aftermath of the toxic injury and the underlying cause to this, may be aerobic or anaerobic bacteria.

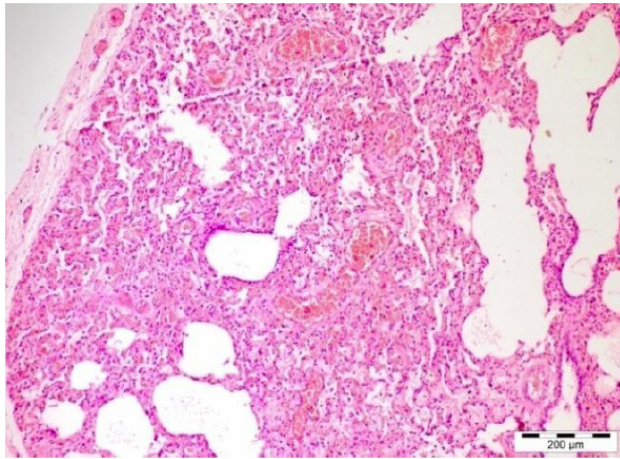


Figure 6: Lungs, Alveolar thickening with hyalinosis, besides serous exudation within alveoli, H&E 20.

Previously reported cases in newly born young foals demonstrated myriad of environmental/surface bacteria accountable for omphalitis, which includes *E. coli* and *Streptococcus zooepidemicus* [11, 12]. Apart from them, *Clostridium perfringens* was found to be largely associated with urachitis and uroperitoneum in neonatal foals [3,9] and more recently *Clostridium sordellii* was incriminated for serious infection to internal umbilical remnant in foals [9]. Notably, something to consider here in this case, is the evident bacterial organisms in the peripheral vascular channel of umbilical zone, apart from the vehement vascular changes (both haemorrhagic and fibrinous), edematous and emphysematous changes noted (in different

organs) were suggestive of endogenous origin, thereby ruling out the possibility of post-mortem contamination due to unhygienic vicinity.

In conclusion, the work reported describes a case of omphalitis in buffalo calf for the first time with possible insinuation towards toxic effect of bacterial origin, originated from torn umbilicus leading to massive vascular changes like haemoperitoneum, fibrino-purulent damage to urachus (urachitis), edematous and haemorrhagic changes in kidney and in urinary bladder, besides cardio-vascular and pneumonic alterations.

REFERENCES

- [1] Abdullah FFJ, Abba Y, Tijjani A, Mohammed K, Muhammad AS, Chung ELT, Saharee AA, Haron AW. Septicaemia associated with omphalitis in a goat kid. *Int J Livestock Res* 2015; d.o.i. 10.5455/ijlr.20150426021357.
- [2] Radostits OM, Gay CC, Blood DC, Hinchcliff KW. In: *Veterinary Medicine. A text book of the diseases of cattle, sheep, pig, goat and horses.* (9th ed), W.B. Saunders, Philadelphia, 2000; pp. 1442-1452.
- [3] Hyman SS, Wilkins PA, Palmer JE, Schaer TP, Del Piero F. *Clostridium perfringens* urachitis and uroperitoneum in 2 neonatal foals. *J Vet Int Med* 2002; 16: 489-493. <https://doi.org/10.1111/j.1939-1676.2002.tb01270.x>
- [4] Naik GS, Ananda KJ, Kavitha RB, Kotresh AM, Shambulingappa BE, Patel SR. Navel ill in new born calves and its successful treatment. *Vet World* 2011; 4: 326-327.
- [5] Luna LG. *Manual of histologic staining methods of Armed Forces Institute of Pathology*, 3rd Edn, McGraw Hill Book Co., New York 1968.
- [6] Pugh DG, Baird NN. In: *Sheep and Goat medicine*, (2nd ed), Elsevier Saunders 3251 Riverport Lane Maryland Heights, Missouri 2012.
- [7] Thedford TR. In: *Goat Health handbook.* (1st ed), Winrock International Route 3 Morrilton, Arkansas 1983; pp. 38-39.
- [8] Bowen JS. Joint ill in goats. In: *the Merck veterinary Manual* 2014. http://www.merckvetmanual.com/mvm/musculoskeletal_system/lameness_goats/joints-ill_in_goats.html
- [9] Ortega J, Daft B, Assis RA, Kinde H, Anthenill L, Odani J, Uzal FA. Infection of internal umbilical remnant in foals by *Clostridium sordellii*. *Vet Pathol* 2007; 44: 269-275. <https://doi.org/10.1354/vp.44-3-269>
- [10] Mendoza FJ, Lopez M, Diez E, Perez-Ecija A, Estepa JC. Uroperitoneum secondary to rupture of the urachus associated with *Clostridium* spp. Infection in a foal: a case report. *Veterinarnii Medicina* 2010; 55: 399-404.
- [11] Adams SB, Fessler JF. Umbilical cord remnant infections in foals: 16 cases (1975-1985). *Journal of American Veterinary Medical Association* 1987; 190: 316-318.
- [12] Smith KC, Blunden AS, Whitwell KE, Dunn KA, Wales AD. A survey of equine abortion, stillbirth and neonatal death in the UK from 1988 to 1997. *Equine Vet J* 2003; 35: 496-501. <https://doi.org/10.2746/042516403775600578>